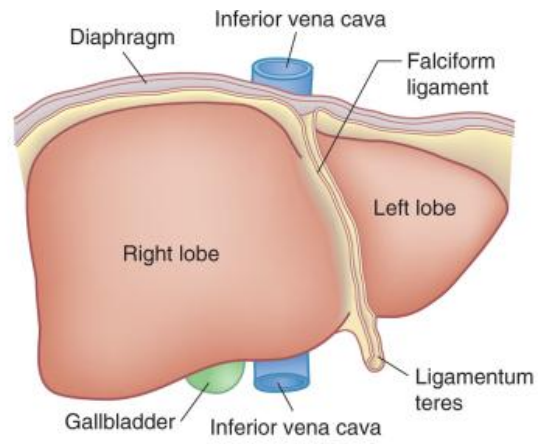
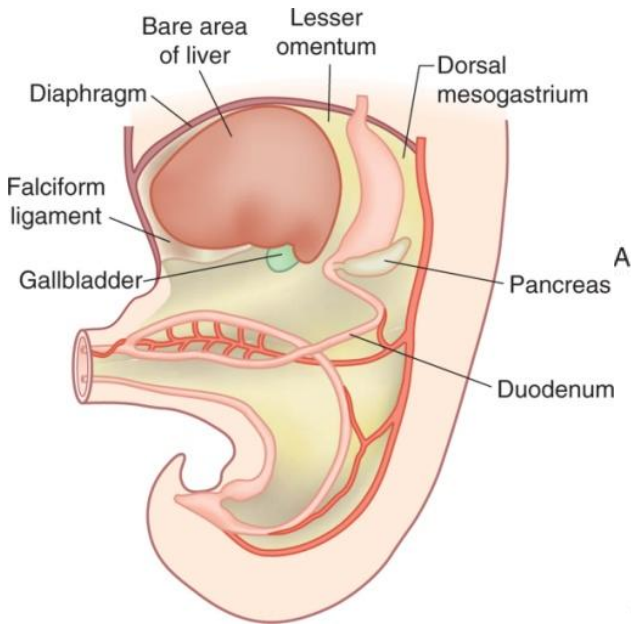
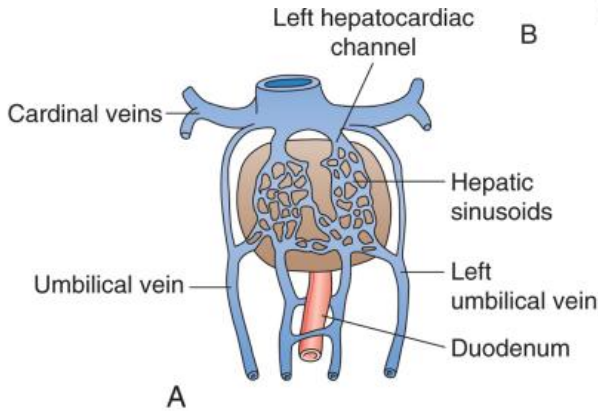
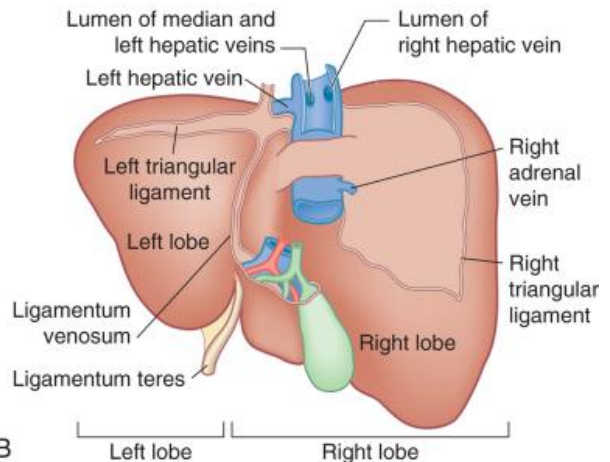


LIVER

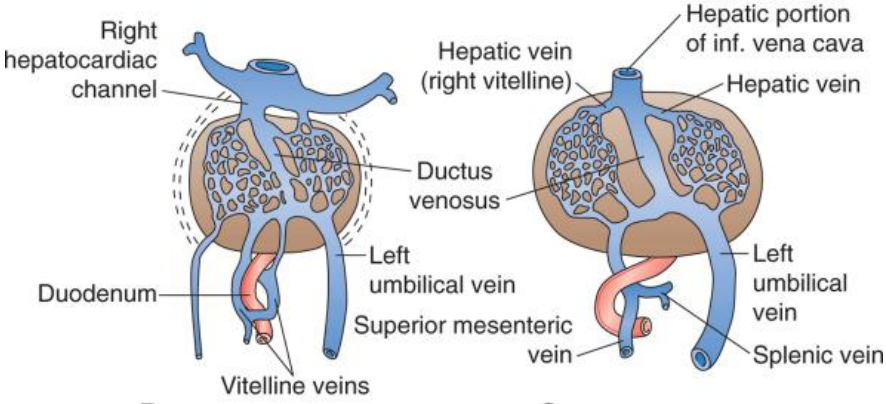


A

B

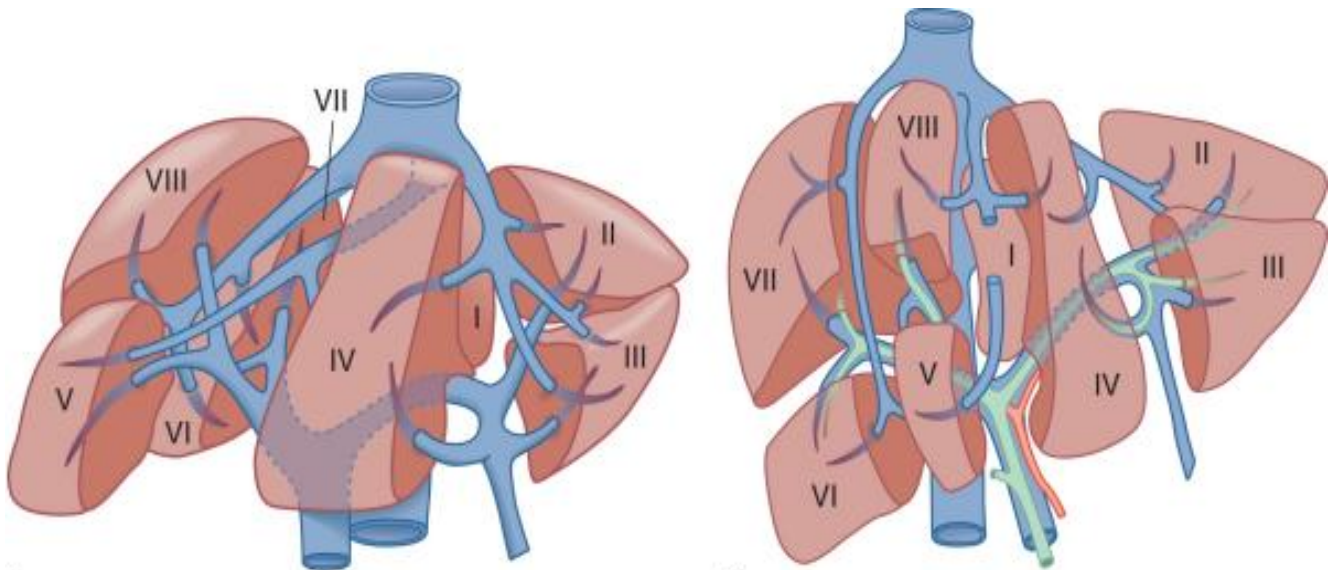


A



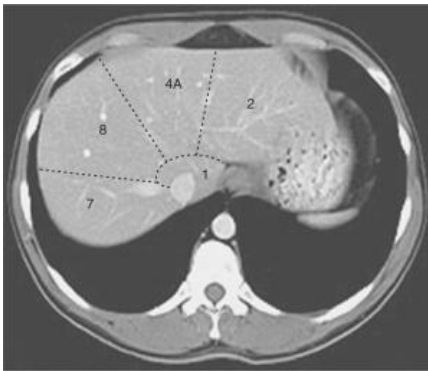
B

C

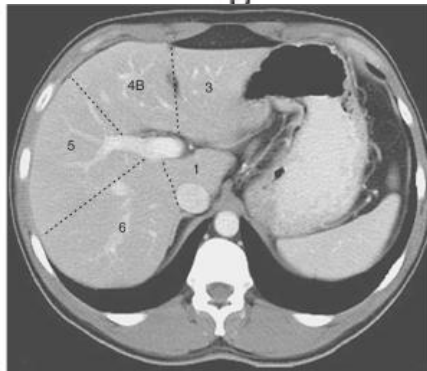


A

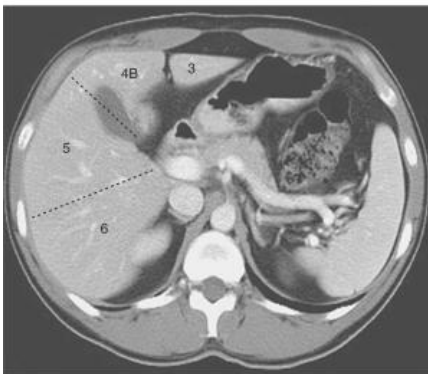
B



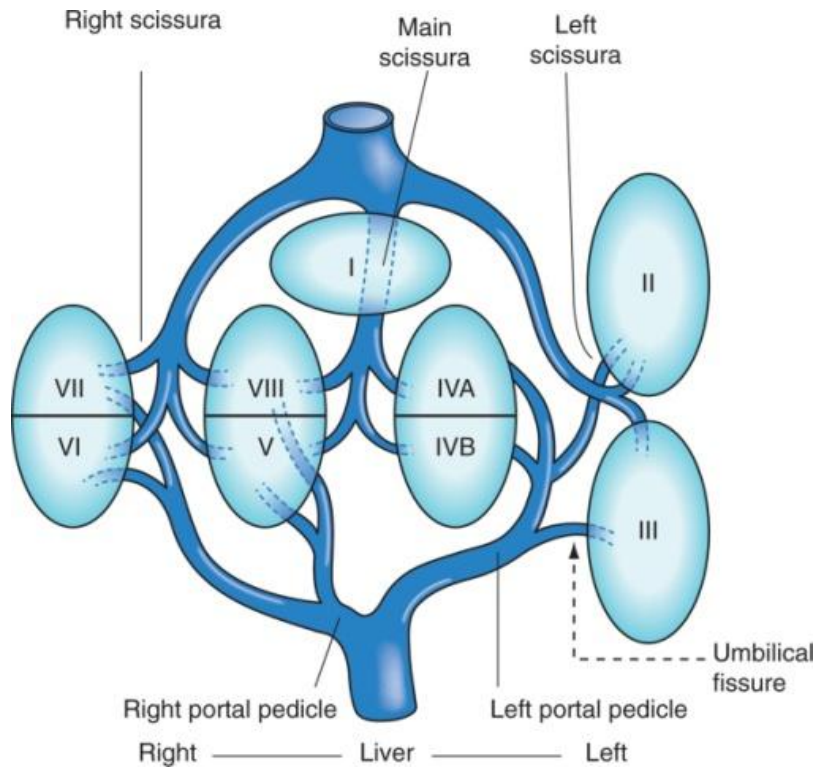
A

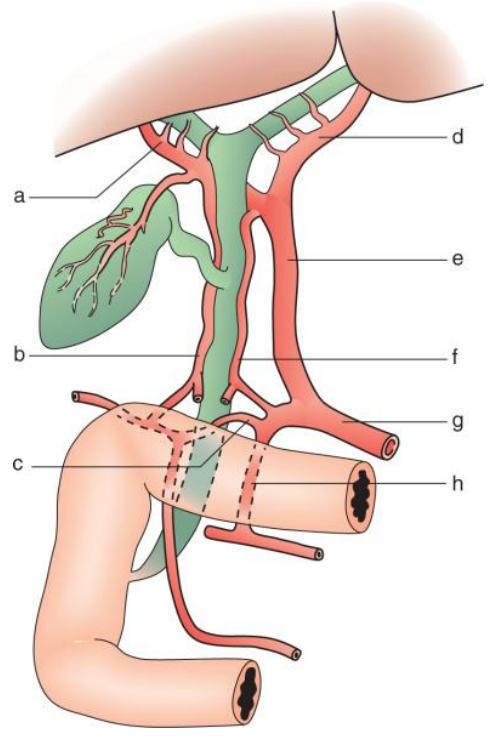
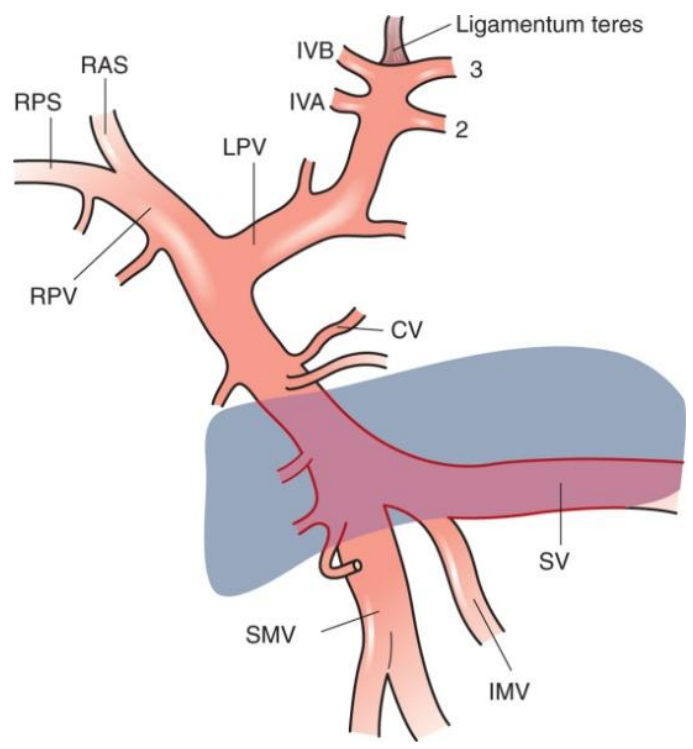
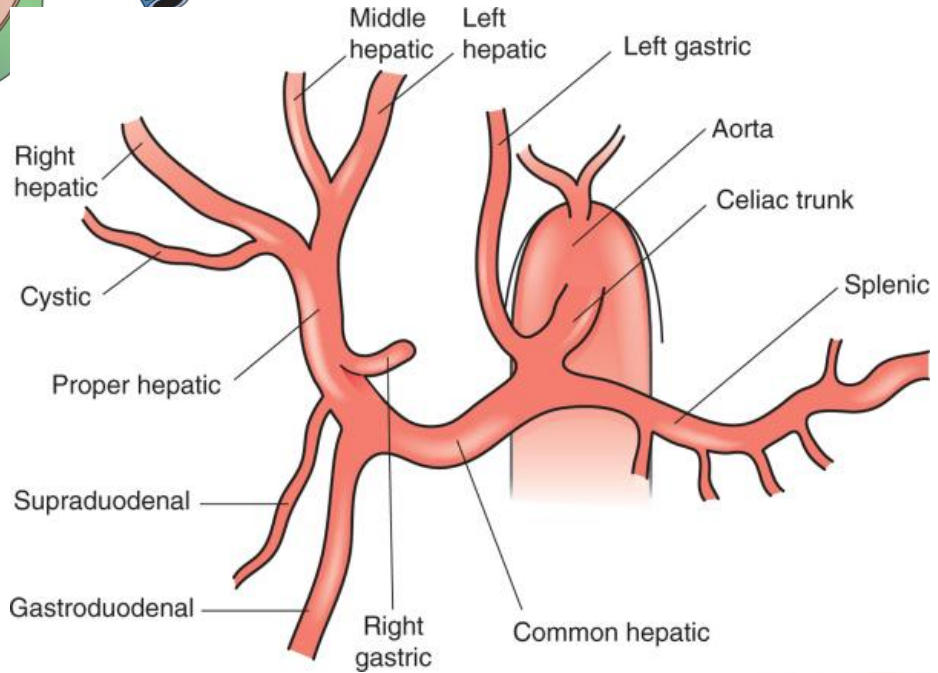
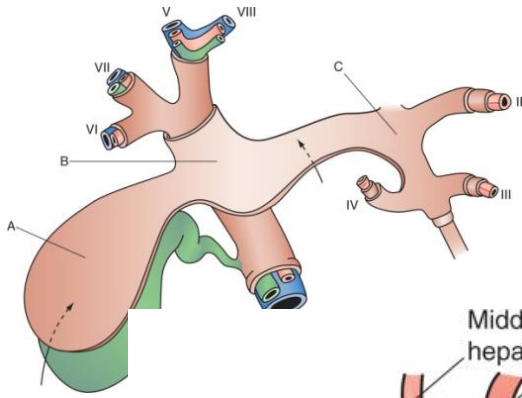


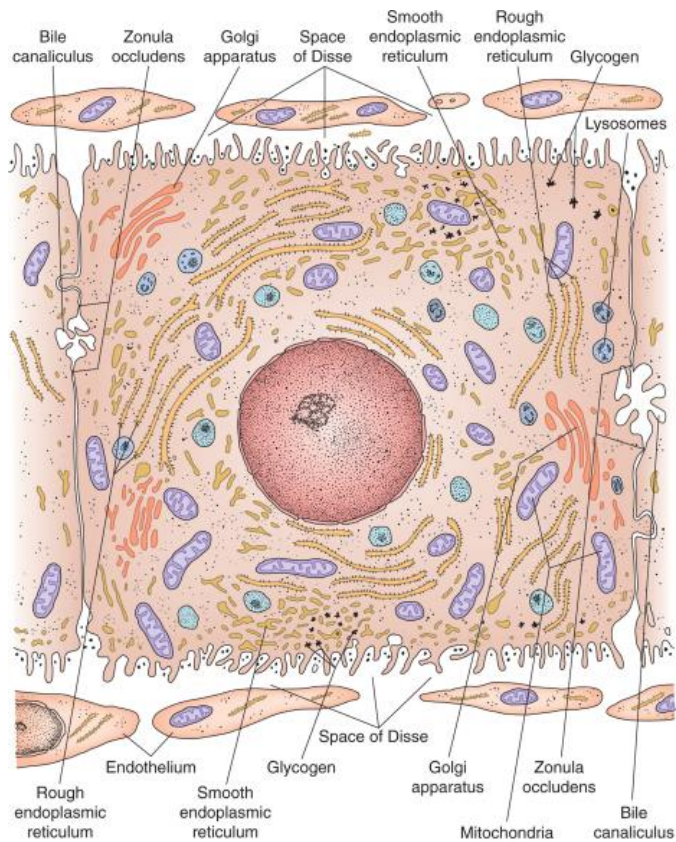
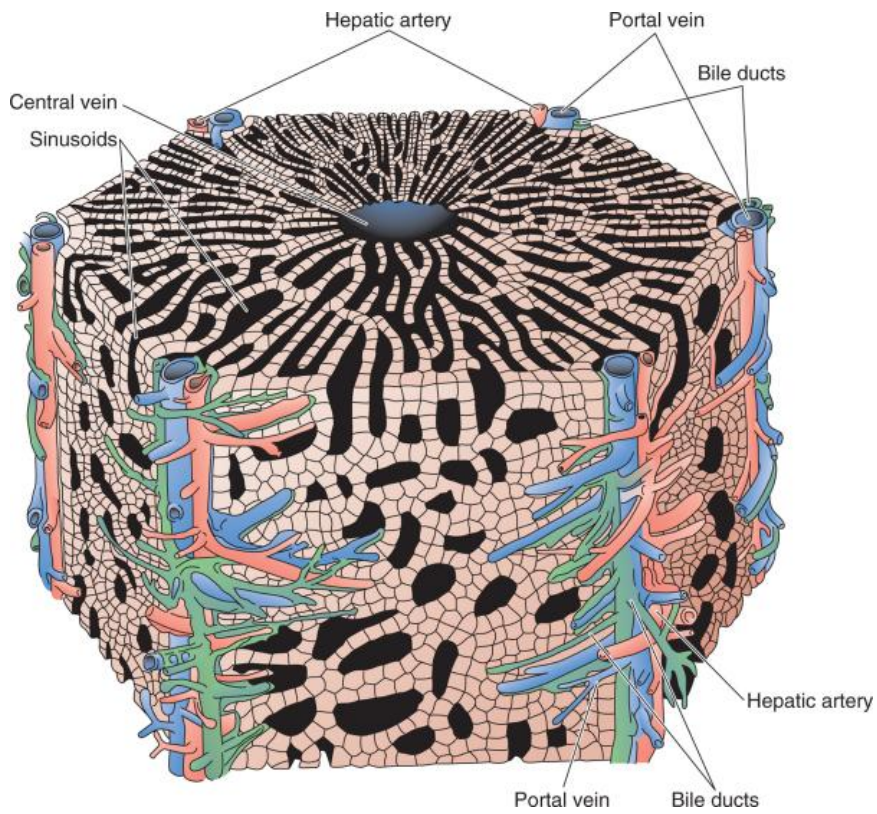
B



C

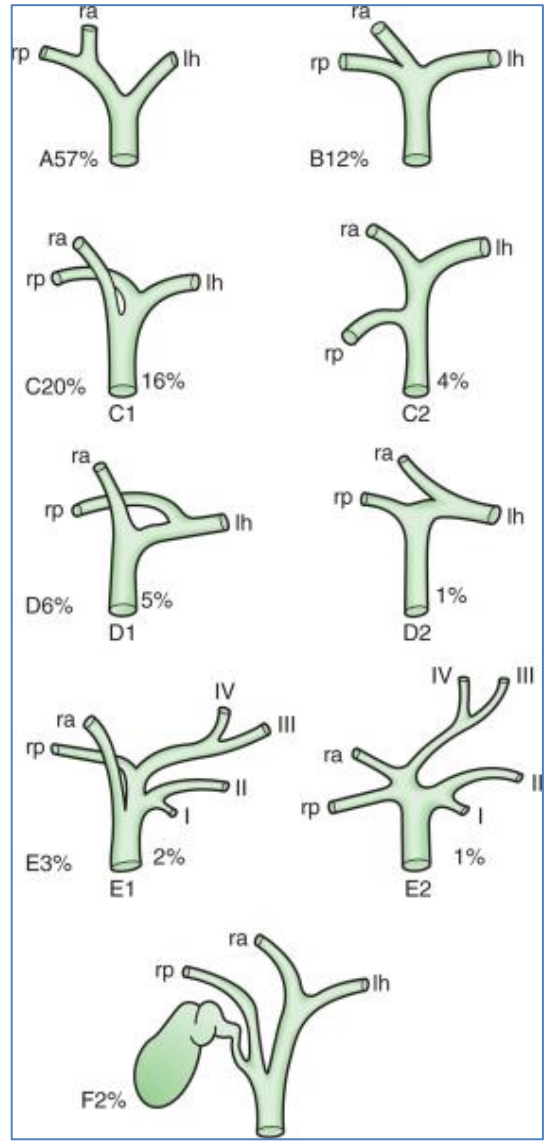
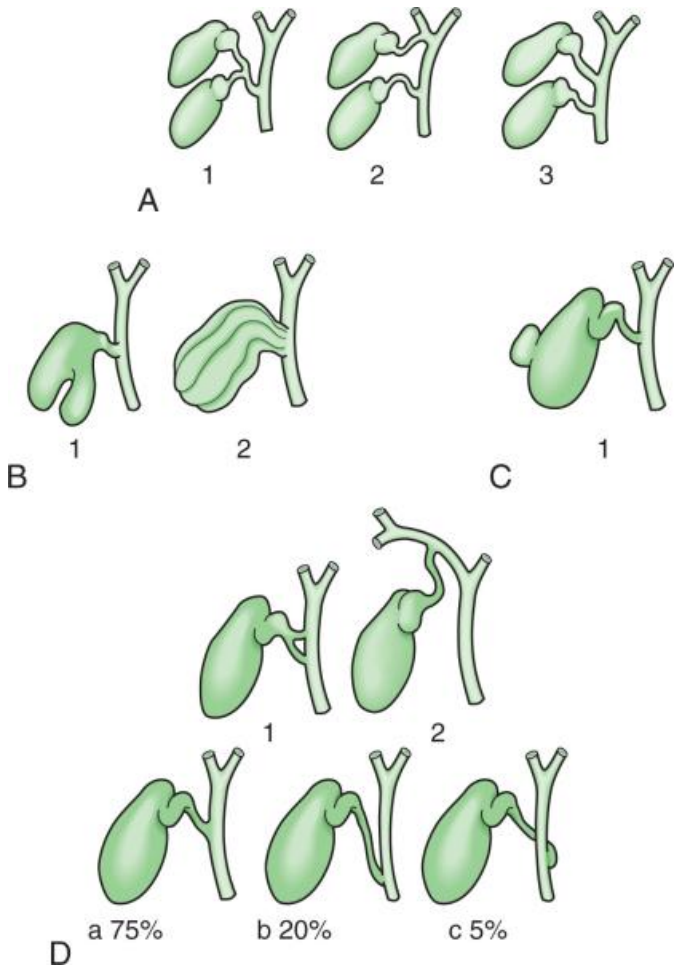
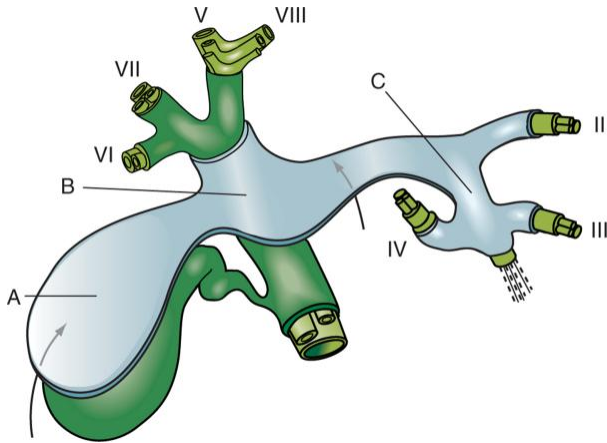


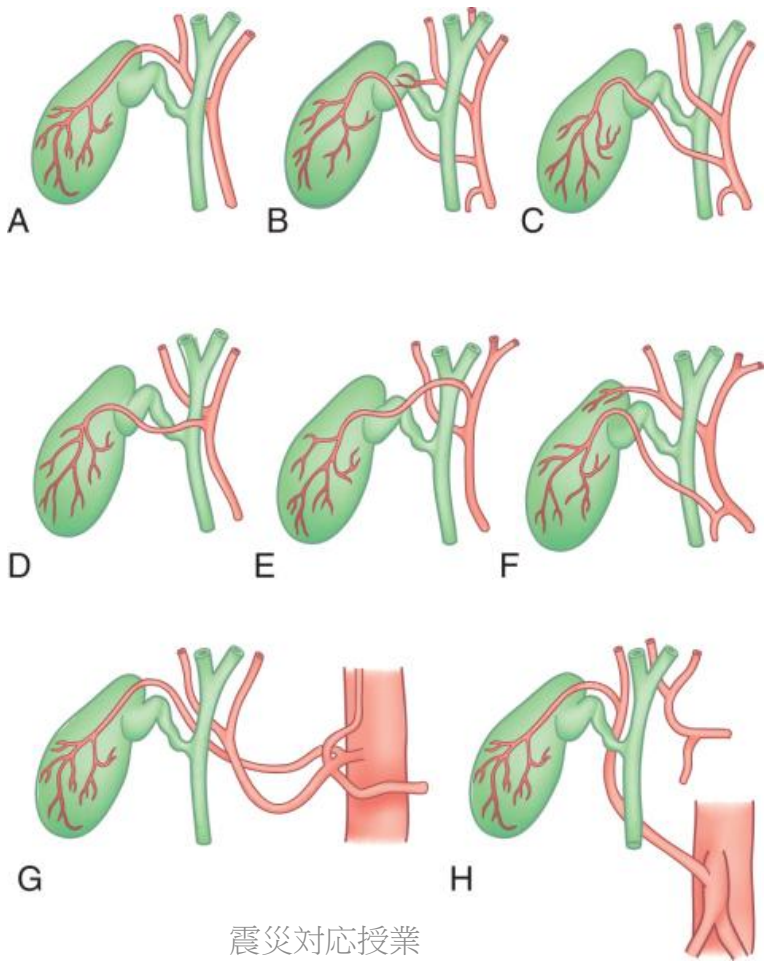
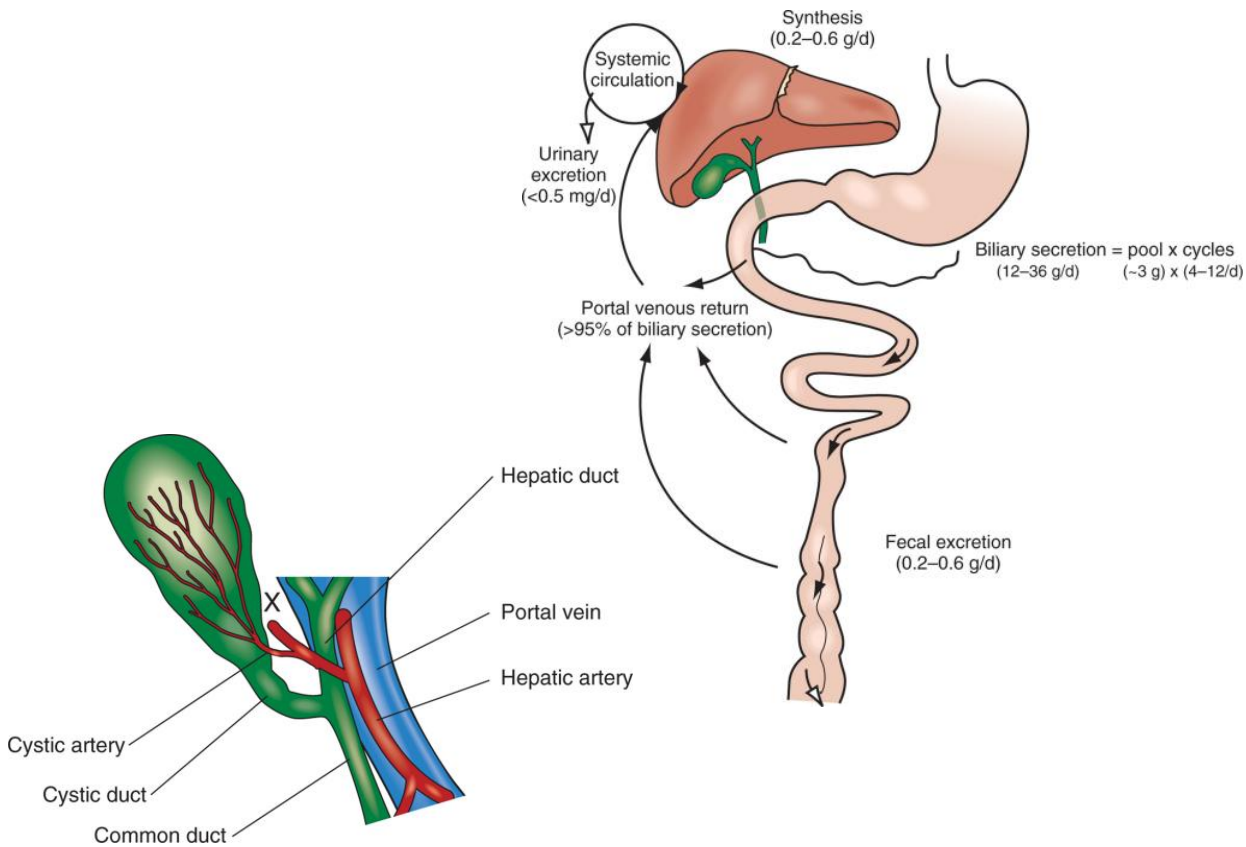




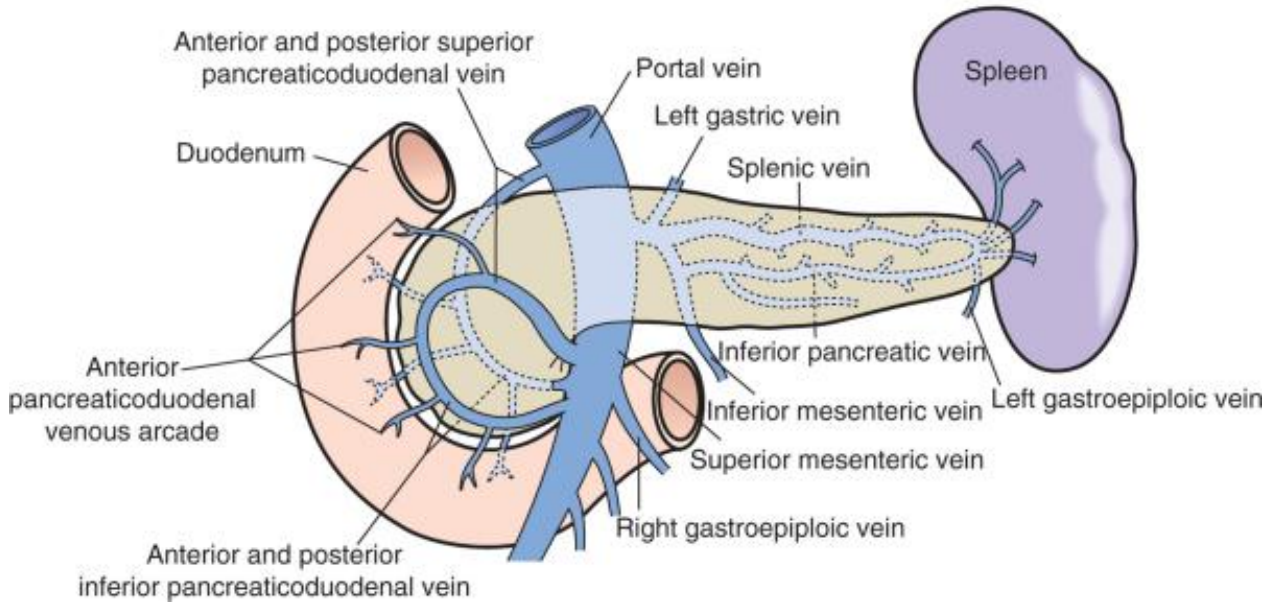
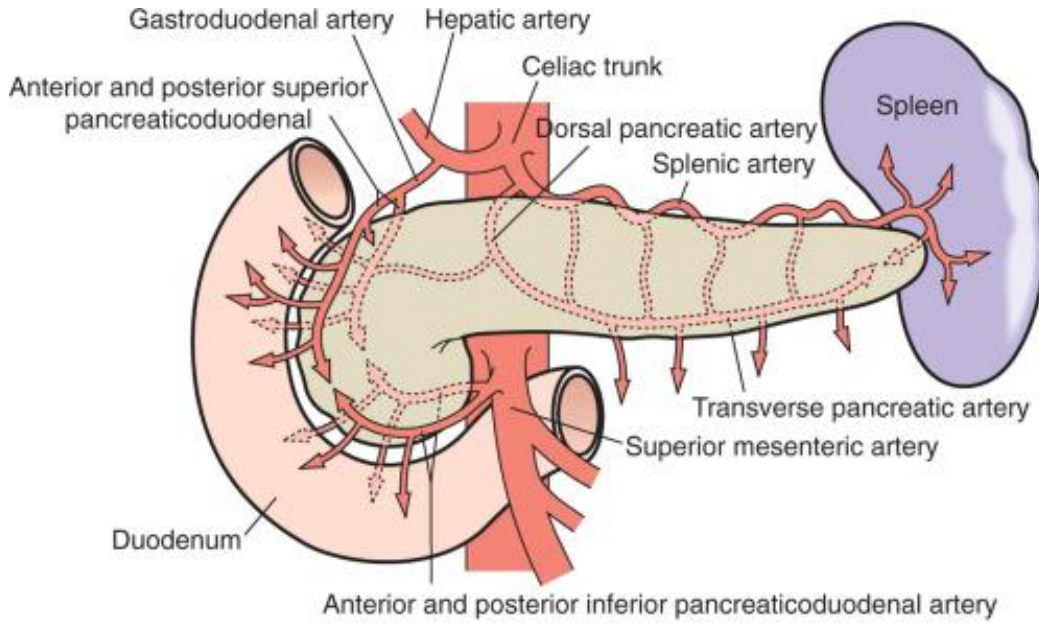
Lumen of sinusoid

BILIARY TREE

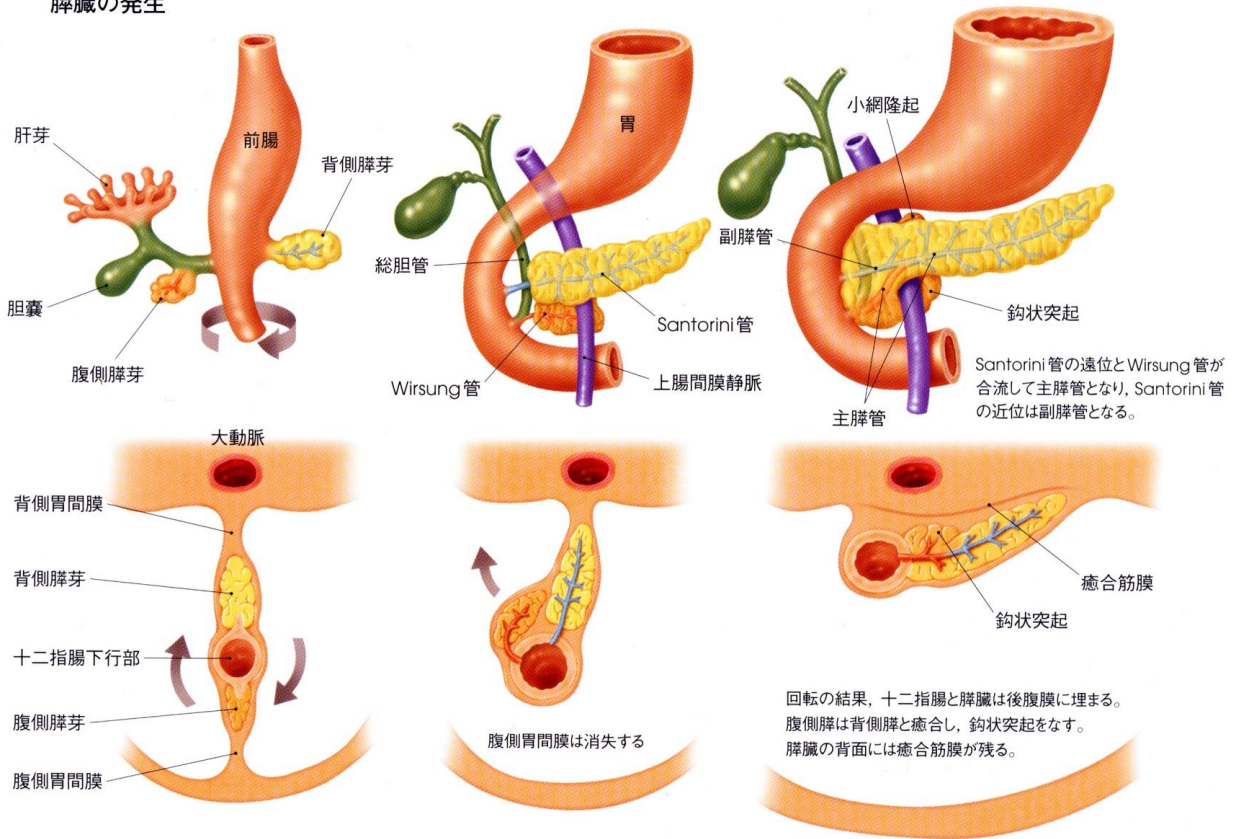




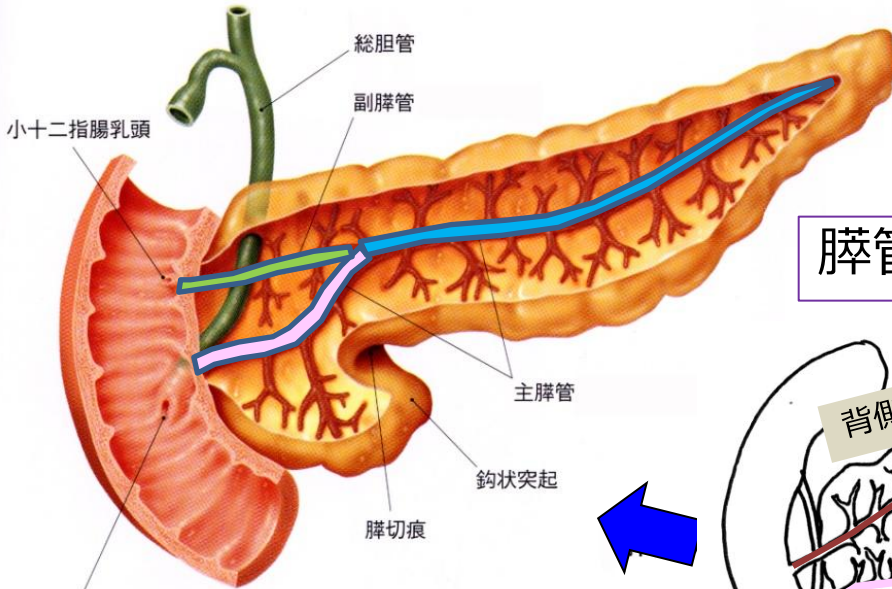
PANCREAS



膵臓の発生



主膵管 : Wirsung管 + Santorini管遠位側
副膵管 : Santorini管近位側



膵管の癒合

背側膵の膵管 : Santorini管
腹側膵の膵管 : Wirsung管

