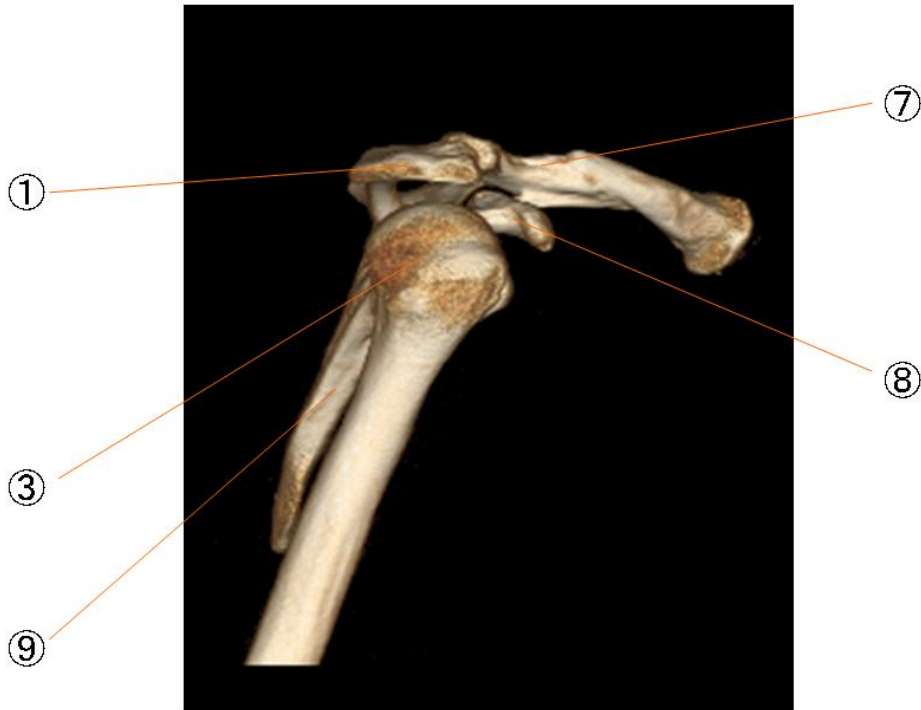


肩関節

- | | |
|-----------|-----------------------------|
| ① 肩峰 | acromion |
| ② 上腕骨の大結節 | greater tubercle of humerus |
| ③ 上腕骨頭 | head of scapula |
| ④ 関節窩 | glenoid cavity |
| ⑤ 上腕骨の外科頸 | surgical neck of humerus |
| ⑥ 肩鎖関節 | acromioclavicular joint |
| ⑦ 鎖骨 | clavicle |
| ⑧ 烏口突起 | coracoid process |
| ⑨ 関節下結節 | infraglenoid tubercle |
| ⑩ 肩甲棘 | spine of scapula |
| ⑪ 棘下窩 | infraspinous fossa |
| ⑫ 棘上窩 | supraspinous fossa |

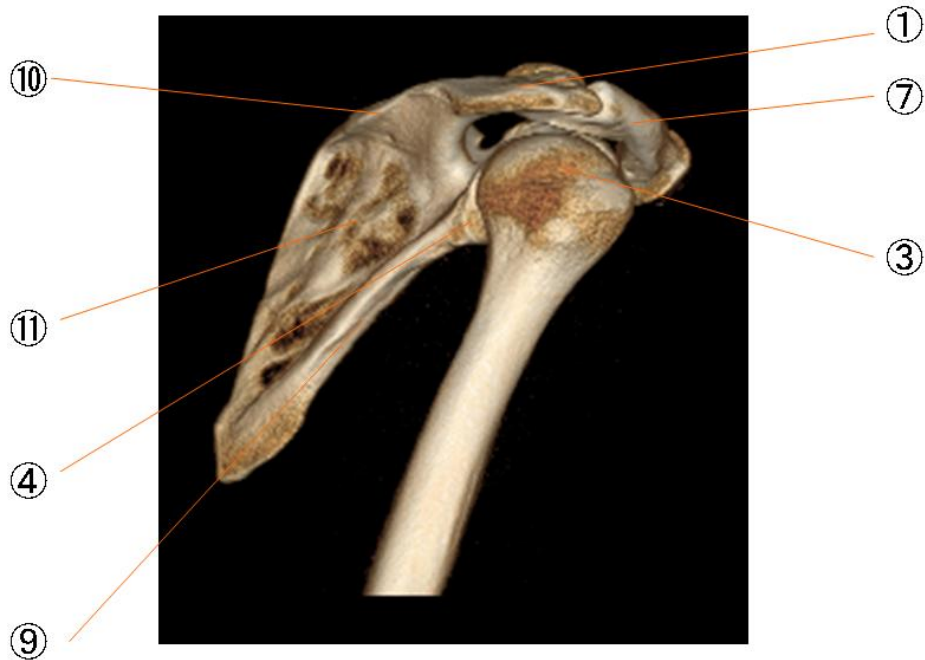肩関節



肩関節

- | | |
|-----------|-----------------------------|
| ① 肩峰 | acromion |
| ② 上腕骨の大結節 | greater tubercle of humerus |
| ③ 上腕骨頭 | head of scapula |
| ④ 関節窩 | glenoid cavity |
| ⑤ 上腕骨の外科頸 | surgical neck of humerus |
| ⑥ 肩鎖関節 | acromioclavicular joint |
| ⑦ 鎖骨 | clavicle |
| ⑧ 烏口突起 | coracoid process |
| ⑨ 関節下結節 | infraglenoid tubercle |
| ⑩ 肩甲棘 | spine of scapula |
| ⑪ 棘下窩 | infraspinous fossa |
| ⑫ 棘上窩 | supraspinous fossa |

肩関節



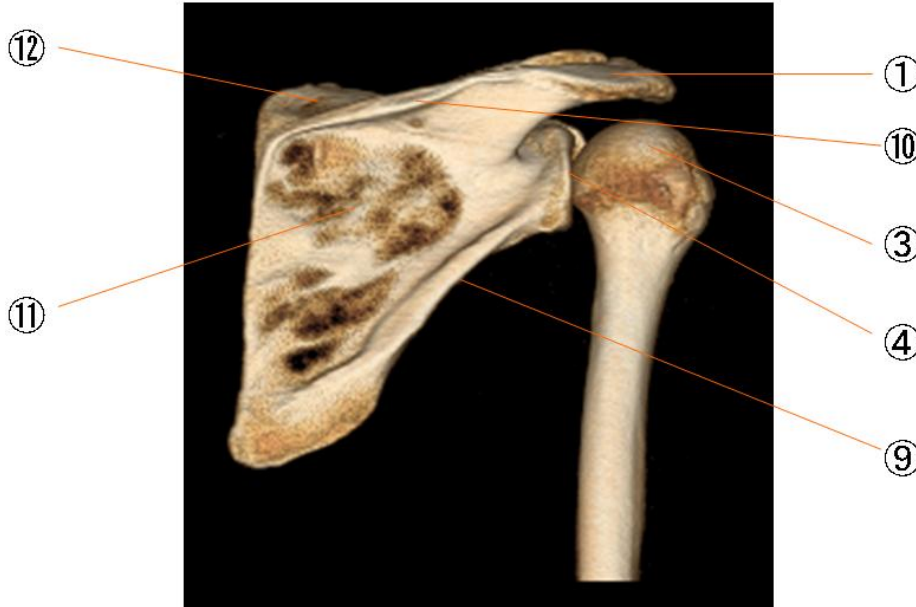
肩関節

- | | |
|-----------|-----------------------------|
| ① 肩峰 | acromion |
| ② 上腕骨の大結節 | greater tubercle of humerus |
| ③ 上腕骨頭 | head of scapula |
| ④ 関節窩 | glenoid cavity |
| ⑤ 上腕骨の外科頸 | surgical neck of humerus |
| ⑥ 肩鎖関節 | acromioclavicular joint |
| ⑦ 鎖骨 | clavicle |
| ⑧ 烏口突起 | coracoid process |
| ⑨ 関節下結節 | infraglenoid tubercle |
| ⑩ 肩甲棘 | spine of scapula |
| ⑪ 棘下窩 | infraspinous fossa |
| ⑫ 棘上窩 | supraspinous fossa |

肩関節

- | | |
|-----------|-----------------------------|
| ① 肩峰 | acromion |
| ② 上腕骨の大結節 | greater tubercle of humerus |
| ③ 上腕骨頭 | head of scapula |
| ④ 関節窩 | glenoid cavity |
| ⑤ 上腕骨の外科頸 | surgical neck of humerus |
| ⑥ 肩鎖関節 | acromioclavicular joint |
| ⑦ 鎖骨 | clavicle |
| ⑧ 烏口突起 | coracoid process |
| ⑨ 関節下結節 | infraglenoid tubercle |
| ⑩ 肩甲棘 | spine of scapula |
| ⑪ 棘下窩 | infraspinous fossa |
| ⑫ 棘上窩 | supraspinous fossa |

肩関節



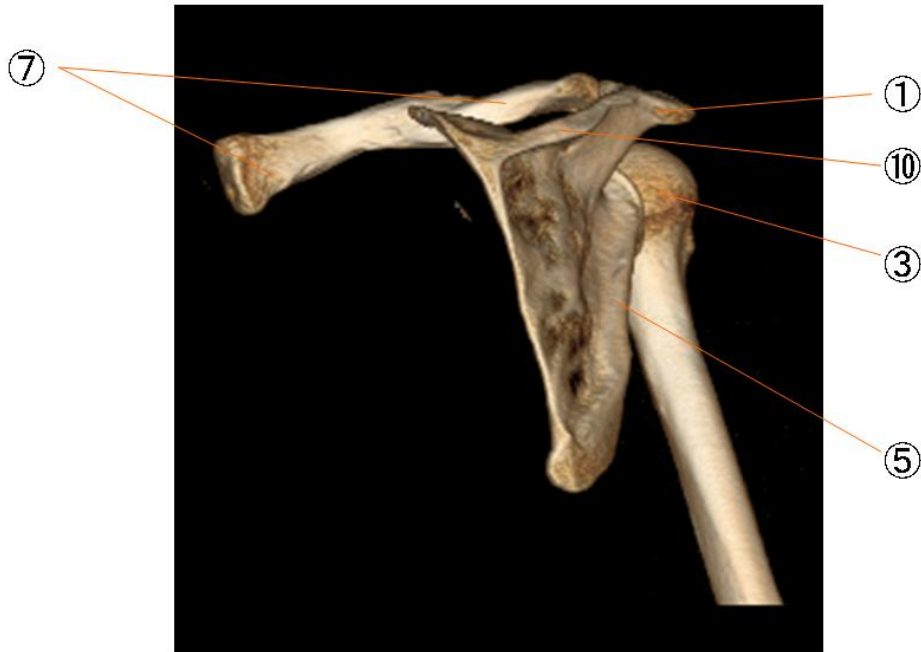
肩関節

- | | |
|-----------|-----------------------------|
| ① 肩峰 | acromion |
| ② 上腕骨の大結節 | greater tubercle of humerus |
| ③ 上腕骨頭 | head of scapula |
| ④ 関節窩 | glenoid cavity |
| ⑤ 上腕骨の外科頸 | surgical neck of humerus |
| ⑥ 肩鎖関節 | acromioclavicular joint |
| ⑦ 鎖骨 | clavicle |
| ⑧ 烏口突起 | coracoid process |
| ⑨ 関節下結節 | infraglenoid tubercle |
| ⑩ 肩甲棘 | spine of scapula |
| ⑪ 棘下窩 | infraspinous fossa |
| ⑫ 棘上窩 | supraspinous fossa |

肩関節

- | | |
|-----------|-----------------------------|
| ① 肩峰 | acromion |
| ② 上腕骨の大結節 | greater tubercle of humerus |
| ③ 上腕骨頭 | head of scapula |
| ④ 関節窩 | glenoid cavity |
| ⑤ 上腕骨の外科頸 | surgical neck of humerus |
| ⑥ 肩鎖関節 | acromioclavicular joint |
| ⑦ 鎖骨 | clavicle |
| ⑧ 烏口突起 | coracoid process |
| ⑨ 関節下結節 | infraglenoid tubercle |
| ⑩ 肩甲棘 | spine of scapula |
| ⑪ 棘下窩 | infraspinous fossa |
| ⑫ 棘上窩 | supraspinous fossa |

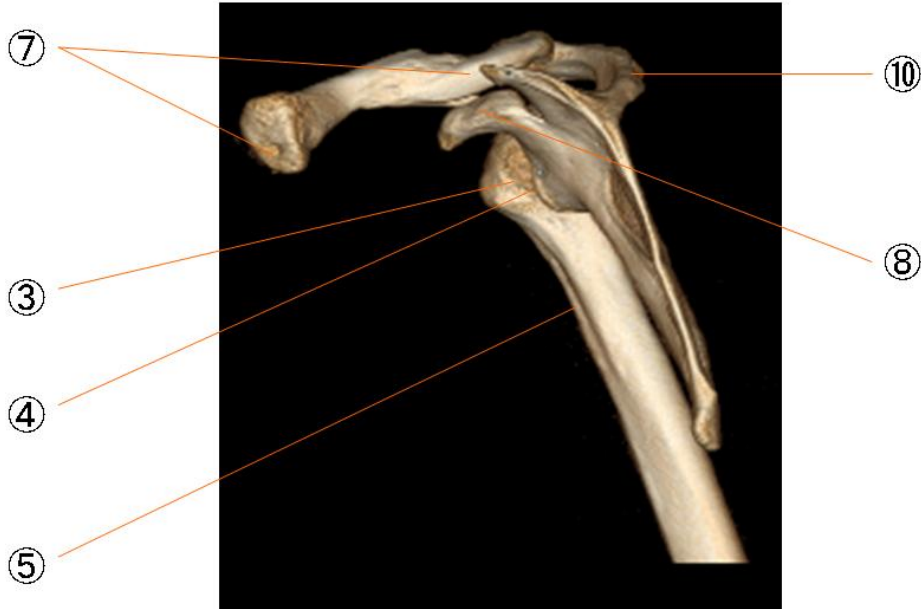
肩関節



肩関節

- | | |
|-----------|-----------------------------|
| ① 肩峰 | acromion |
| ② 上腕骨の大結節 | greater tubercle of humerus |
| ③ 上腕骨頭 | head of scapula |
| ④ 関節窩 | glenoid cavity |
| ⑤ 上腕骨の外科頸 | surgical neck of humerus |
| ⑥ 肩鎖関節 | acromioclavicular joint |
| ⑦ 鎖骨 | clavicle |
| ⑧ 烏口突起 | coracoid process |
| ⑨ 関節下結節 | infraglenoid tubercle |
| ⑩ 肩甲棘 | spine of scapula |
| ⑪ 棘下窩 | infraspinous fossa |
| ⑫ 棘上窩 | supraspinous fossa |

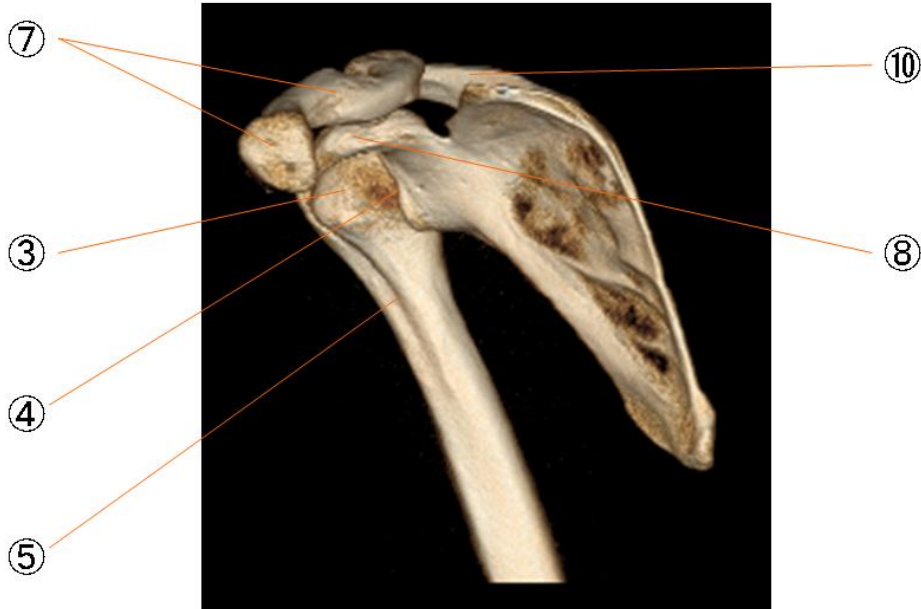
肩関節



肩関節

- | | |
|-----------|-----------------------------|
| ① 肩峰 | acromion |
| ② 上腕骨の大結節 | greater tubercle of humerus |
| ③ 上腕骨頭 | head of scapula |
| ④ 関節窩 | glenoid cavity |
| ⑤ 上腕骨の外科頸 | surgical neck of humerus |
| ⑥ 肩鎖関節 | acromioclavicular joint |
| ⑦ 鎖骨 | clavicle |
| ⑧ 烏口突起 | coracoid process |
| ⑨ 関節下結節 | infraglenoid tubercle |
| ⑩ 肩甲棘 | spine of scapula |
| ⑪ 棘下窩 | infraspinous fossa |
| ⑫ 棘上窩 | supraspinous fossa |

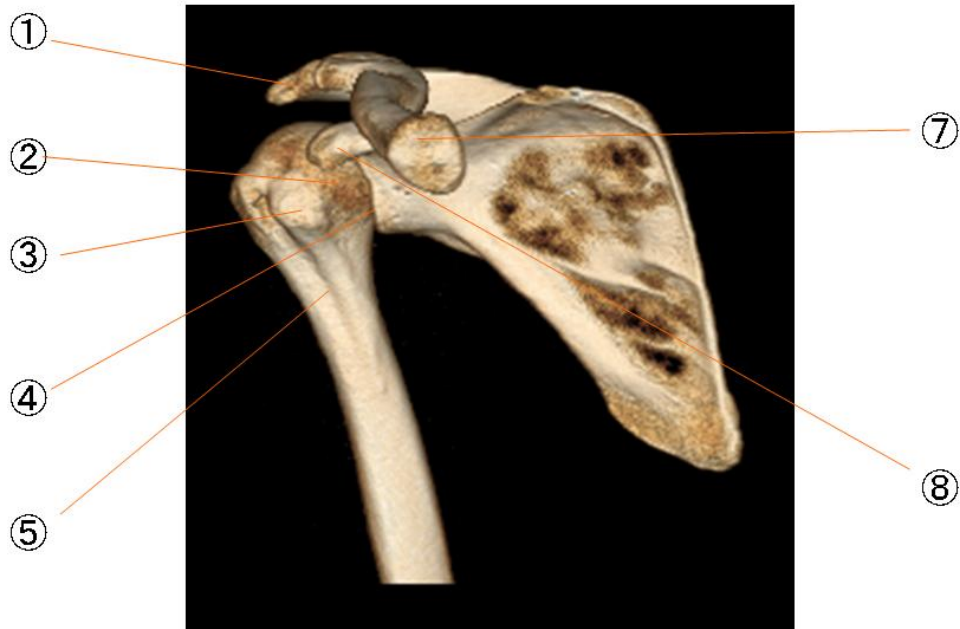肩関節



肩関節

- | | |
|-----------|-----------------------------|
| ① 肩峰 | acromion |
| ② 上腕骨の大結節 | greater tubercle of humerus |
| ③ 上腕骨頭 | head of scapula |
| ④ 関節窩 | glenoid cavity |
| ⑤ 上腕骨の外科頸 | surgical neck of humerus |
| ⑥ 肩鎖関節 | acromioclavicular joint |
| ⑦ 鎖骨 | clavicle |
| ⑧ 烏口突起 | coracoid process |
| ⑨ 関節下結節 | infraglenoid tubercle |
| ⑩ 肩甲棘 | spine of scapula |
| ⑪ 棘下窩 | infraspinous fossa |
| ⑫ 棘上窩 | supraspinous fossa |

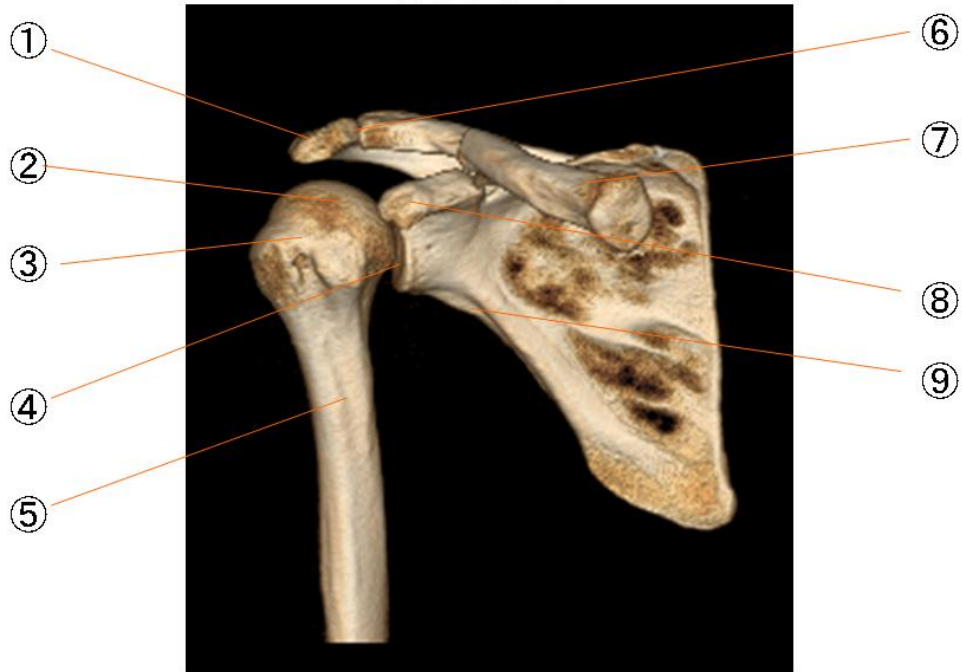肩関節



肩関節

- | | |
|-----------|-----------------------------|
| ① 肩峰 | acromion |
| ② 上腕骨の大結節 | greater tubercle of humerus |
| ③ 上腕骨頭 | head of scapula |
| ④ 関節窩 | glenoid cavity |
| ⑤ 上腕骨の外科頸 | surgical neck of humerus |
| ⑥ 肩鎖関節 | acromioclavicular joint |
| ⑦ 鎖骨 | clavicle |
| ⑧ 烏口突起 | coracoid process |
| ⑨ 関節下結節 | infraglenoid tubercle |
| ⑩ 肩甲棘 | spine of scapula |
| ⑪ 棘下窩 | infraspinous fossa |
| ⑫ 棘上窩 | supraspinous fossa |

肩関節



肩関節

- | | |
|-----------|-----------------------------|
| ① 肩峰 | acromion |
| ② 上腕骨の大結節 | greater tubercle of humerus |
| ③ 上腕骨頭 | head of scapula |
| ④ 関節窩 | glenoid cavity |
| ⑤ 上腕骨の外科頸 | surgical neck of humerus |
| ⑥ 肩鎖関節 | acromioclavicular joint |
| ⑦ 鎖骨 | clavicle |
| ⑧ 烏口突起 | coracoid process |
| ⑨ 関節下結節 | infraglenoid tubercle |
| ⑩ 肩甲棘 | spine of scapula |
| ⑪ 棘下窩 | infraspinous fossa |
| ⑫ 棘上窩 | supraspinous fossa |

肩関節

- | | |
|-----------|-----------------------------|
| ① 肩峰 | acromion |
| ② 上腕骨の大結節 | greater tubercle of humerus |
| ③ 上腕骨頭 | head of scapula |
| ④ 関節窩 | glenoid cavity |
| ⑤ 上腕骨の外科頸 | surgical neck of humerus |
| ⑥ 肩鎖関節 | acromioclavicular joint |
| ⑦ 鎖骨 | clavicle |
| ⑧ 烏口突起 | coracoid process |
| ⑨ 関節下結節 | infraglenoid tubercle |
| ⑩ 肩甲棘 | spine of scapula |
| ⑪ 棘下窩 | infraspinous fossa |
| ⑫ 棘上窩 | supraspinous fossa |