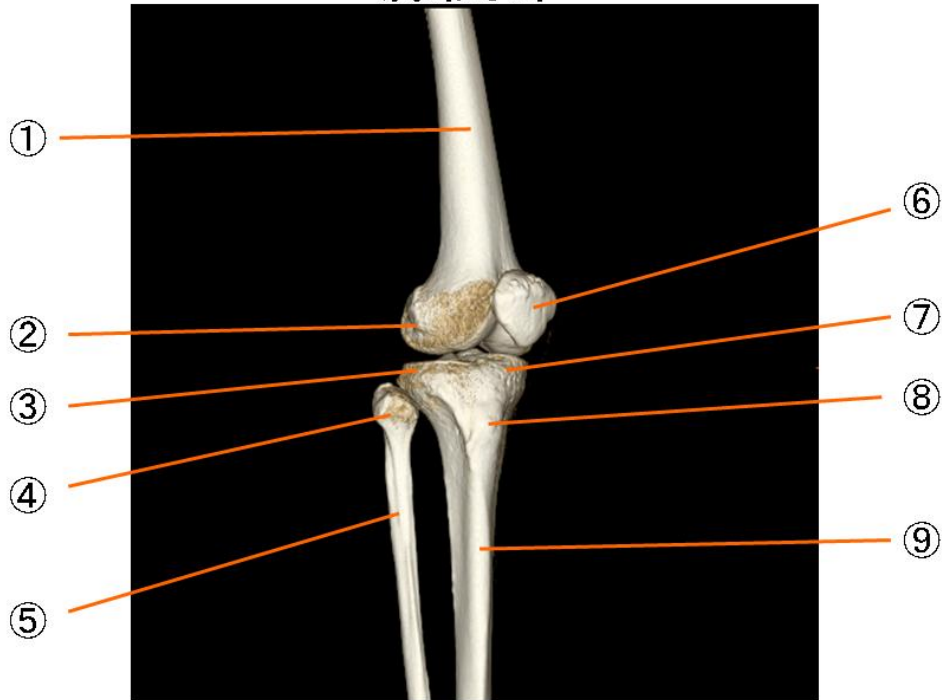


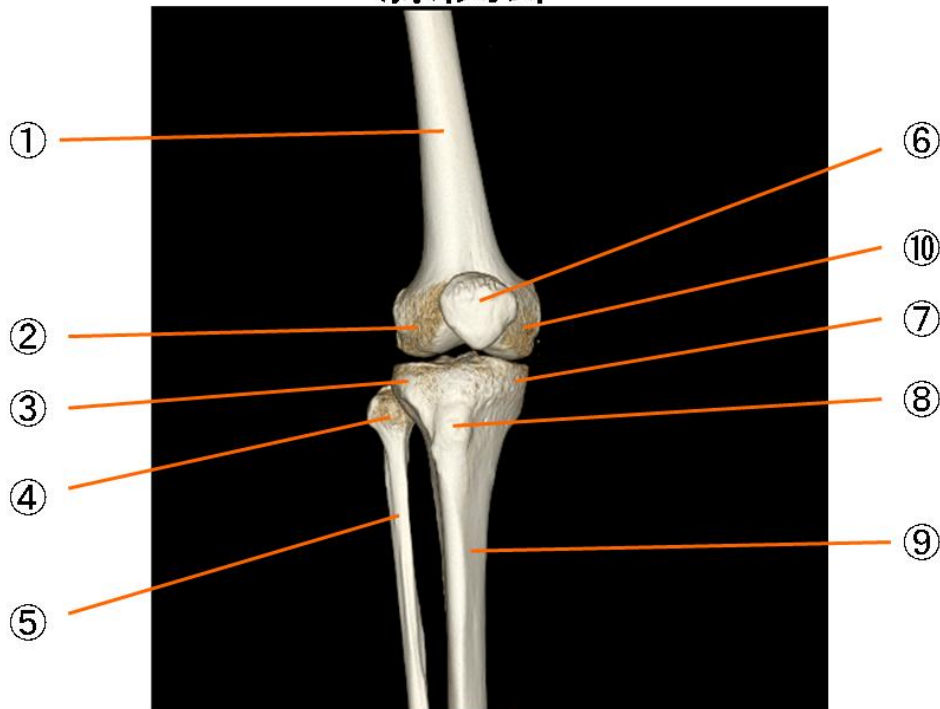
# 膝関節



## 膝関節

- |            |                                 |
|------------|---------------------------------|
| ① 大腿骨      | femur                           |
| ② 大腿骨の外側上顆 | lateral epicondyle of femur     |
| ③ 脛骨の外側顆   | lateral condyle of tibia        |
| ④ 腓骨頭      | head of fibula                  |
| ⑤ 腓骨       | fibula                          |
| ⑥ 膝蓋骨      | patella                         |
| ⑦ 脛骨の内側頭   | medial condyle of tibia         |
| ⑧ 脛骨粗面     | tuberosity of tibia             |
| ⑨ 脛骨体      | shaft of tibia                  |
| ⑩ 大腿骨の内側上顆 | medial epikondyle of femur      |
| ⑪ 大腿骨の外側顆  | lateral condyle of femur        |
| ⑫ 大腿骨の膝窩面  | popliteal surdface of femur     |
| ⑬ 大腿骨の顆間窩  | intercondylar fossa of femur    |
| ⑭ 脛骨の顆間隆起  | intercondylar eminence of tibia |

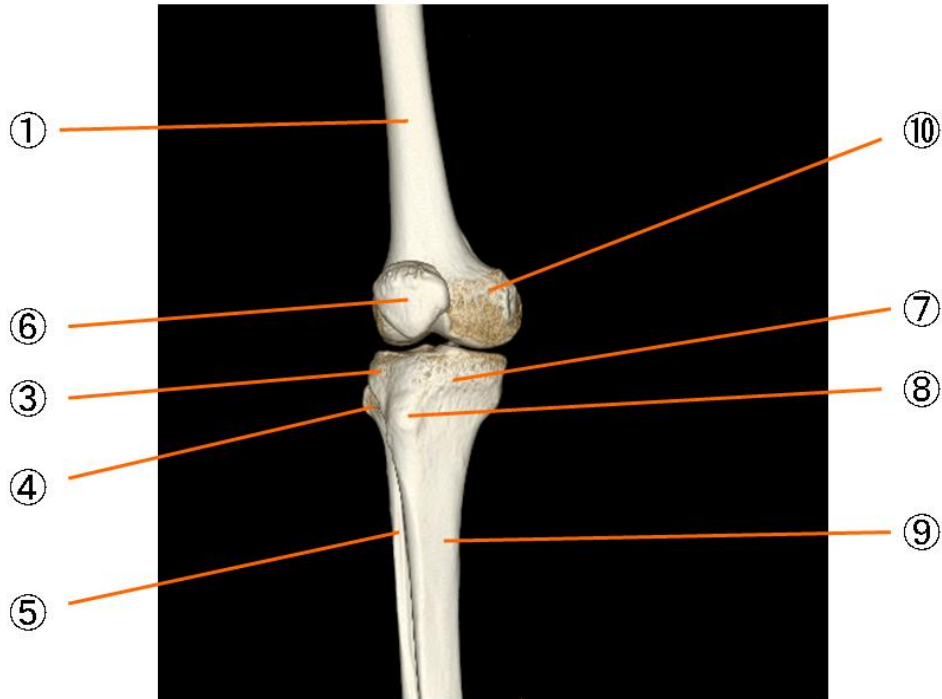
# 膝関節



## 膝関節

- |            |                                 |
|------------|---------------------------------|
| ① 大腿骨      | femur                           |
| ② 大腿骨の外側上顆 | lateral epicondyle of femur     |
| ③ 脛骨の外側顆   | lateral condyle of tibia        |
| ④ 腓骨頭      | head of fibula                  |
| ⑤ 腓骨       | fibula                          |
| ⑥ 膝蓋骨      | patella                         |
| ⑦ 脛骨の内側頭   | medial condyle of tibia         |
| ⑧ 脛骨粗面     | tuberosity of tibia             |
| ⑨ 脛骨体      | shaft of tibia                  |
| ⑩ 大腿骨の内側上顆 | medial epicondyle of femur      |
| ⑪ 大腿骨の外側顆  | lateral condyle of femur        |
| ⑫ 大腿骨の膝窩面  | popliteal surface of femur      |
| ⑬ 大腿骨の顆間窩  | intercondylar fossa of femur    |
| ⑭ 脛骨の顆間隆起  | intercondylar eminence of tibia |

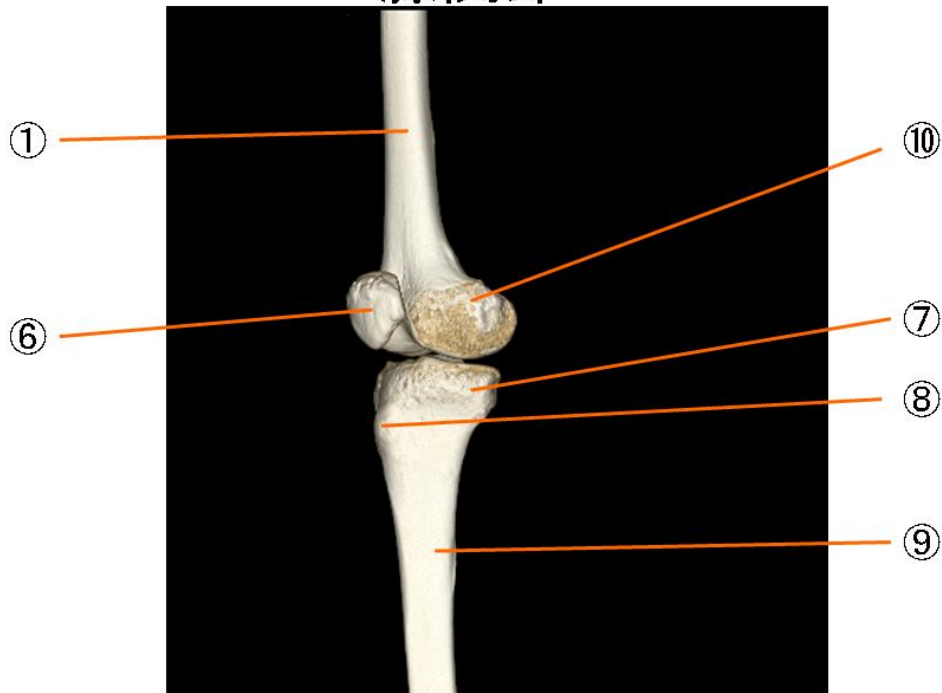
# 膝関節



## 膝関節

- |            |                                 |
|------------|---------------------------------|
| ① 大腿骨      | femur                           |
| ② 大腿骨の外側上顆 | lateral epicondyle of femur     |
| ③ 脛骨の外側顆   | lateral condyle of tibia        |
| ④ 腓骨頭      | head of fibula                  |
| ⑤ 腓骨       | fibula                          |
| ⑥ 膝蓋骨      | patella                         |
| ⑦ 脛骨の内側頭   | medial condyle of tibia         |
| ⑧ 脛骨粗面     | tuberosity of tibia             |
| ⑨ 脛骨体      | shaft of tibia                  |
| ⑩ 大腿骨の内側上顆 | medial epikondyle of femur      |
| ⑪ 大腿骨の外側顆  | lateral condyle of femur        |
| ⑫ 大腿骨の膝窩面  | popliteal surdface of femur     |
| ⑬ 大腿骨の顆間窩  | intercondylar fossa of femur    |
| ⑭ 脛骨の顆間隆起  | intercondylar eminence of tibia |

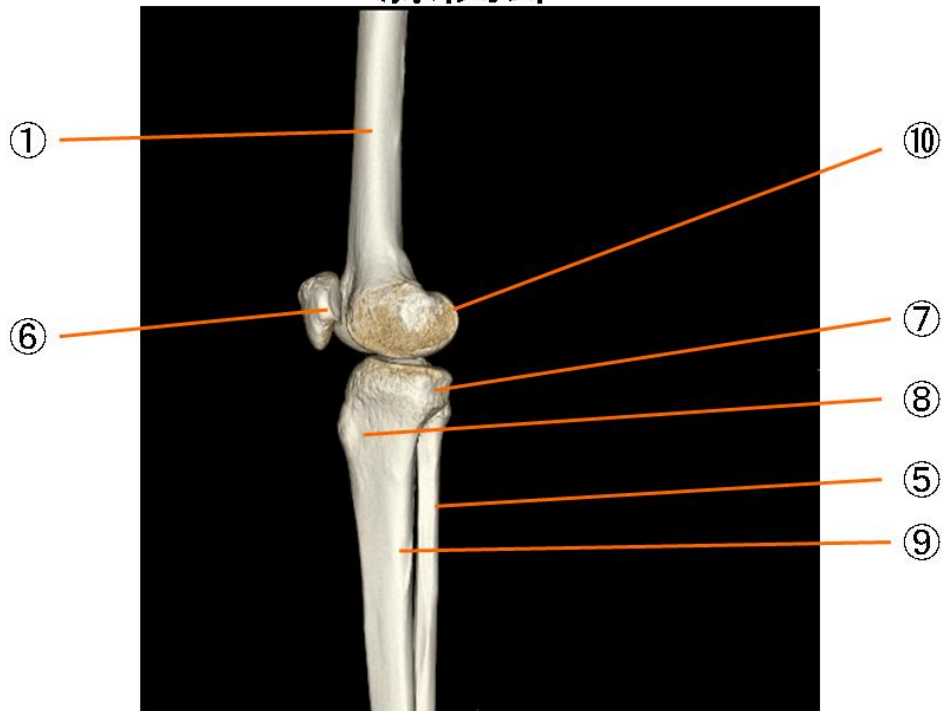
# 膝関節



## 膝関節

- |            |                                 |
|------------|---------------------------------|
| ① 大腿骨      | femur                           |
| ② 大腿骨の外側上顆 | lateral epicondyle of femur     |
| ③ 脛骨の外側顆   | lateral condyle of tibia        |
| ④ 腓骨頭      | head of fibula                  |
| ⑤ 腓骨       | fibula                          |
| ⑥ 膝蓋骨      | patella                         |
| ⑦ 脛骨の内側頭   | medial condyle of tibia         |
| ⑧ 脛骨粗面     | tuberosity of tibia             |
| ⑨ 脛骨体      | shaft of tibia                  |
| ⑩ 大腿骨の内側上顆 | medial epikondyle of femur      |
| ⑪ 大腿骨の外側顆  | lateral condyle of femur        |
| ⑫ 大腿骨の膝窩面  | popliteal surdface of femur     |
| ⑬ 大腿骨の顆間窩  | intercondylar fossa of femur    |
| ⑭ 脛骨の顆間隆起  | intercondylar eminence of tibia |

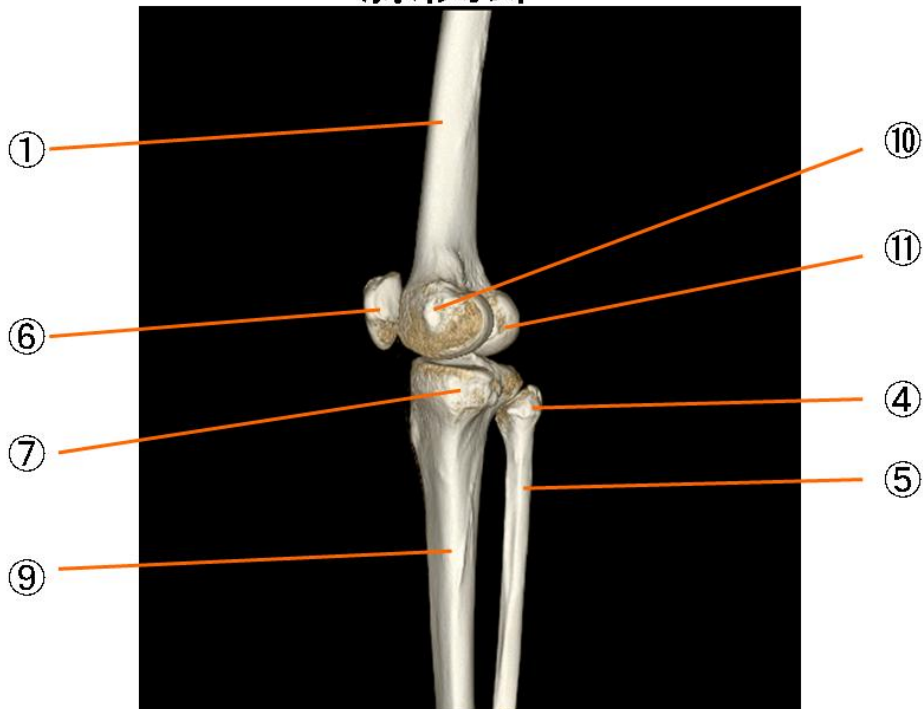
# 膝関節



## 膝関節

- |            |                                 |
|------------|---------------------------------|
| ① 大腿骨      | femur                           |
| ② 大腿骨の外側上顆 | lateral epicondyle of femur     |
| ③ 脛骨の外側顆   | lateral condyle of tibia        |
| ④ 腓骨頭      | head of fibula                  |
| ⑤ 腓骨       | fibula                          |
| ⑥ 膝蓋骨      | patella                         |
| ⑦ 脛骨の内側頭   | medial condyle of tibia         |
| ⑧ 脛骨粗面     | tuberosity of tibia             |
| ⑨ 脛骨体      | shaft of tibia                  |
| ⑩ 大腿骨の内側上顆 | medial epikondyle of femur      |
| ⑪ 大腿骨の外側顆  | lateral condyle of femur        |
| ⑫ 大腿骨の膝窩面  | popliteal surdface of femur     |
| ⑬ 大腿骨の顆間窩  | intercondylar fossa of femur    |
| ⑭ 脛骨の顆間隆起  | intercondylar eminence of tibia |

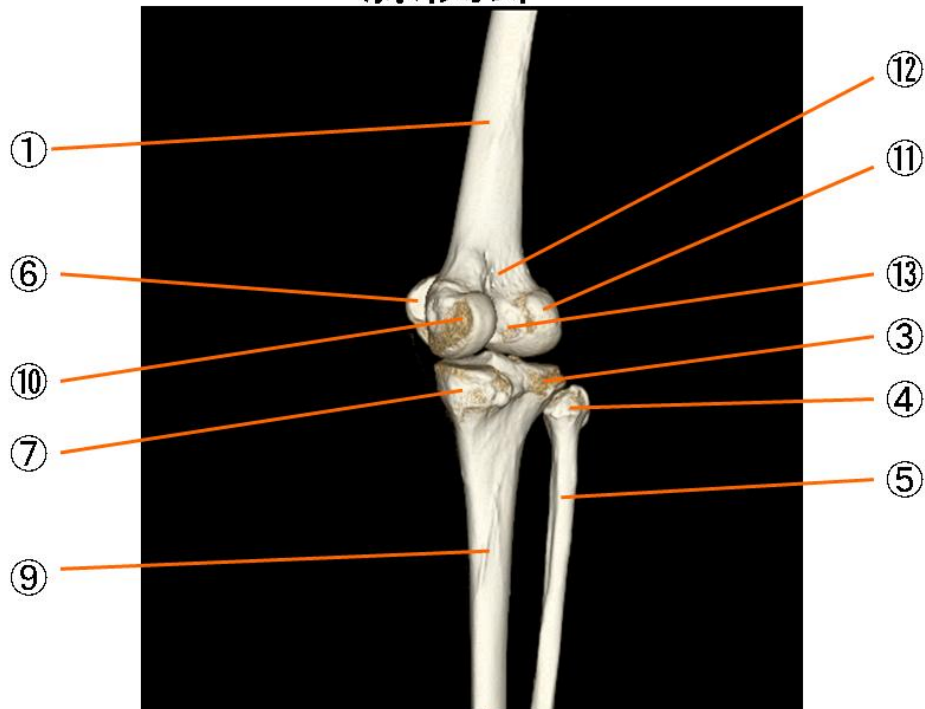
# 膝関節



## 膝関節

- |            |                                 |
|------------|---------------------------------|
| ① 大腿骨      | femur                           |
| ② 大腿骨の外側上顆 | lateral epicondyle of femur     |
| ③ 脛骨の外側顆   | lateral condyle of tibia        |
| ④ 腓骨頭      | head of fibula                  |
| ⑤ 腓骨       | fibula                          |
| ⑥ 膝蓋骨      | patella                         |
| ⑦ 脛骨の内側頭   | medial condyle of tibia         |
| ⑧ 脛骨粗面     | tuberosity of tibia             |
| ⑨ 脛骨体      | shaft of tibia                  |
| ⑩ 大腿骨の内側上顆 | medial epicondyle of femur      |
| ⑪ 大腿骨の外側顆  | lateral condyle of femur        |
| ⑫ 大腿骨の膝窩面  | popliteal surface of femur      |
| ⑬ 大腿骨の顆間窩  | intercondylar fossa of femur    |
| ⑭ 脛骨の顆間隆起  | intercondylar eminence of tibia |

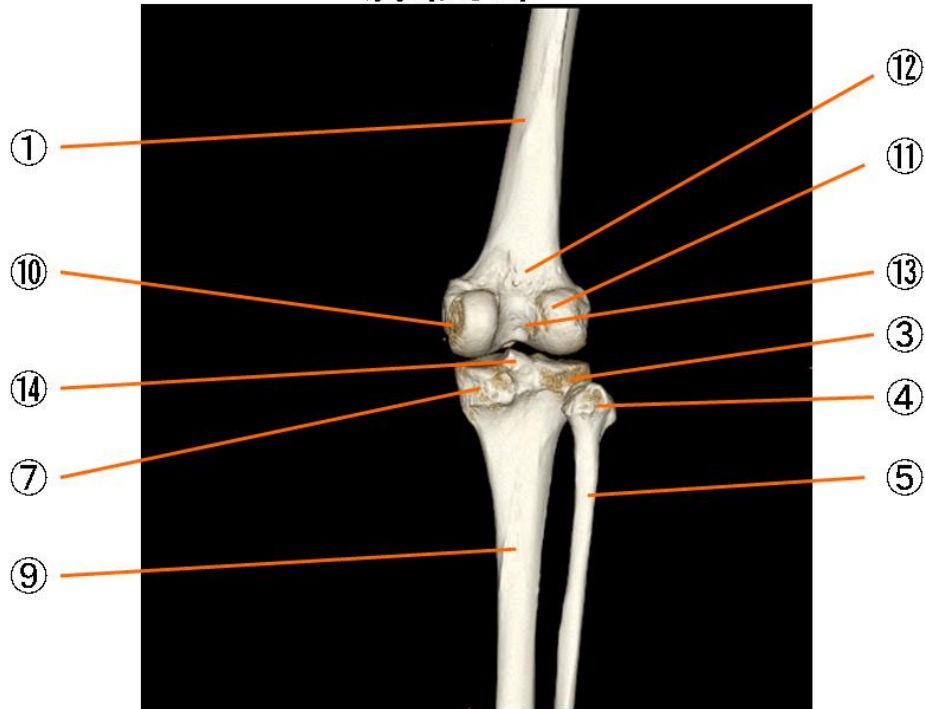
# 膝関節



## 膝関節

- |            |                                 |
|------------|---------------------------------|
| ① 大腿骨      | femur                           |
| ② 大腿骨の外側上顆 | lateral epicondyle of femur     |
| ③ 脛骨の外側顆   | lateral condyle of tibia        |
| ④ 腓骨頭      | head of fibula                  |
| ⑤ 腓骨       | fibula                          |
| ⑥ 膝蓋骨      | patella                         |
| ⑦ 脛骨の内側頭   | medial condyle of tibia         |
| ⑧ 脛骨粗面     | tuberosity of tibia             |
| ⑨ 脛骨体      | shaft of tibia                  |
| ⑩ 大腿骨の内側上顆 | medial epicondyle of femur      |
| ⑪ 大腿骨の外側顆  | lateral condyle of femur        |
| ⑫ 大腿骨の膝窩面  | popliteal surface of femur      |
| ⑬ 大腿骨の顆間窩  | intercondylar fossa of femur    |
| ⑭ 脛骨の顆間隆起  | intercondylar eminence of tibia |

# 膝関節

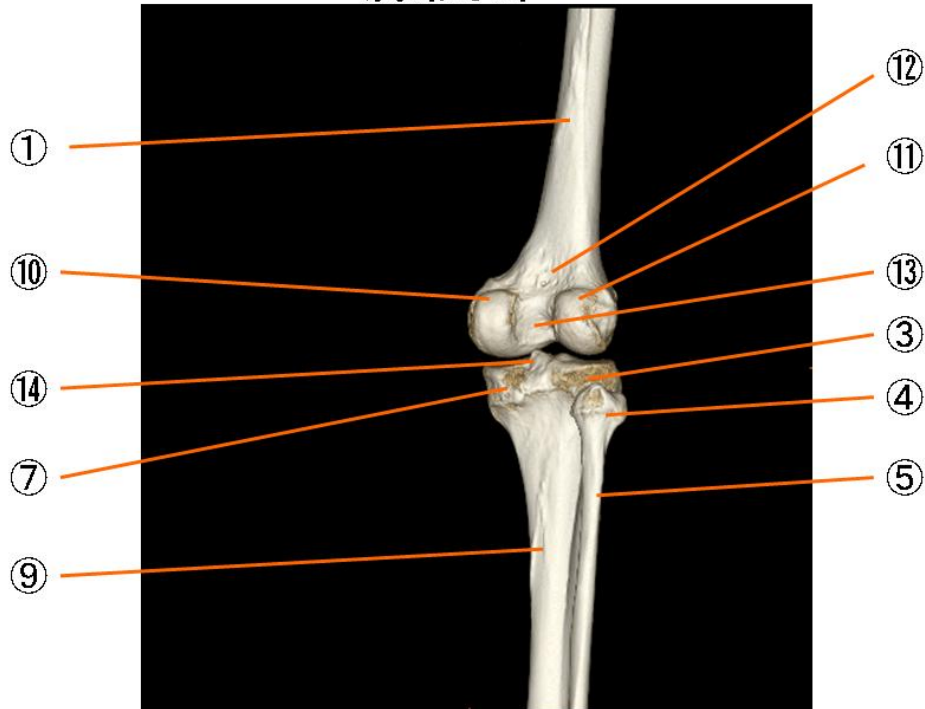


## 膝関節

- |            |                                 |
|------------|---------------------------------|
| ① 大腿骨      | femur                           |
| ② 大腿骨の外側上顆 | lateral epicondyle of femur     |
| ③ 脛骨の外側顆   | lateral condyle of tibia        |
| ④ 腓骨頭      | head of fibula                  |
| ⑤ 腓骨       | fibula                          |
| ⑥ 膝蓋骨      | patella                         |
| ⑦ 脛骨の内側頭   | medial condyle of tibia         |
| ⑧ 脛骨粗面     | tuberosity of tibia             |
| ⑨ 脛骨体      | shaft of tibia                  |
| ⑩ 大腿骨の内側上顆 | medial epicondyle of femur      |
| ⑪ 大腿骨の外側顆  | lateral condyle of femur        |
| ⑫ 大腿骨の膝窩面  | popliteal surface of femur      |
| ⑬ 大腿骨の顆間窩  | intercondylar fossa of femur    |
| ⑭ 脛骨の顆間隆起  | intercondylar eminence of tibia |



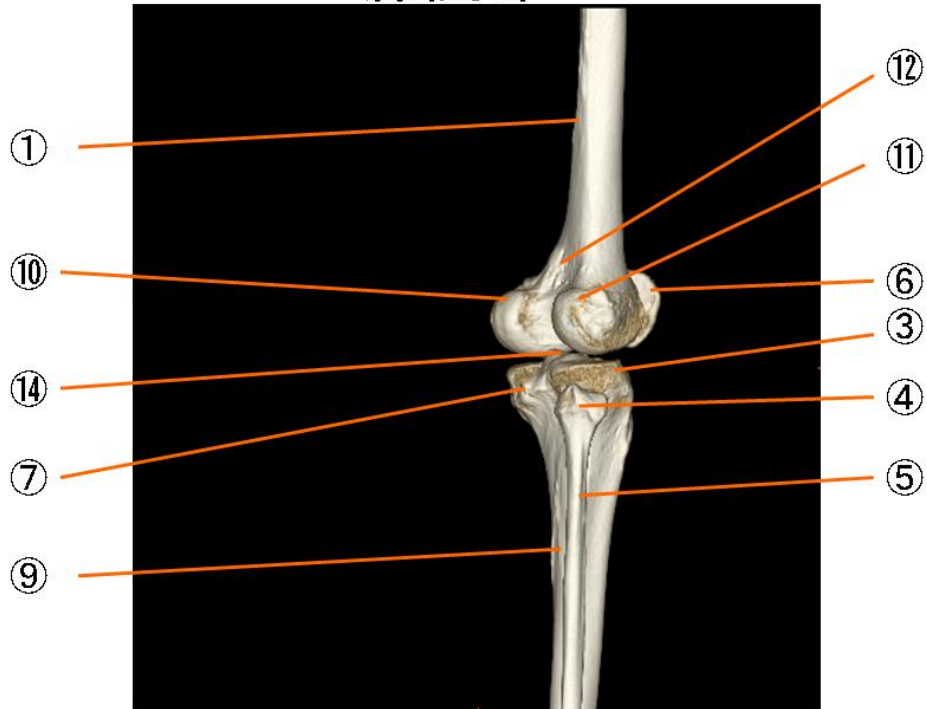
# 膝関節



## 膝関節

- |            |                                 |
|------------|---------------------------------|
| ① 大腿骨      | femur                           |
| ② 大腿骨の外側上顆 | lateral epicondyle of femur     |
| ③ 脛骨の外側顆   | lateral condyle of tibia        |
| ④ 腓骨頭      | head of fibula                  |
| ⑤ 腓骨       | fibula                          |
| ⑥ 膝蓋骨      | patella                         |
| ⑦ 脛骨の内側頭   | medial condyle of tibia         |
| ⑧ 脛骨粗面     | tuberosity of tibia             |
| ⑨ 脛骨体      | shaft of tibia                  |
| ⑩ 大腿骨の内側上顆 | medial epicondyle of femur      |
| ⑪ 大腿骨の外側顆  | lateral condyle of femur        |
| ⑫ 大腿骨の膝窩面  | popliteal surface of femur      |
| ⑬ 大腿骨の顆間窩  | intercondylar fossa of femur    |
| ⑭ 脛骨の顆間隆起  | intercondylar eminence of tibia |

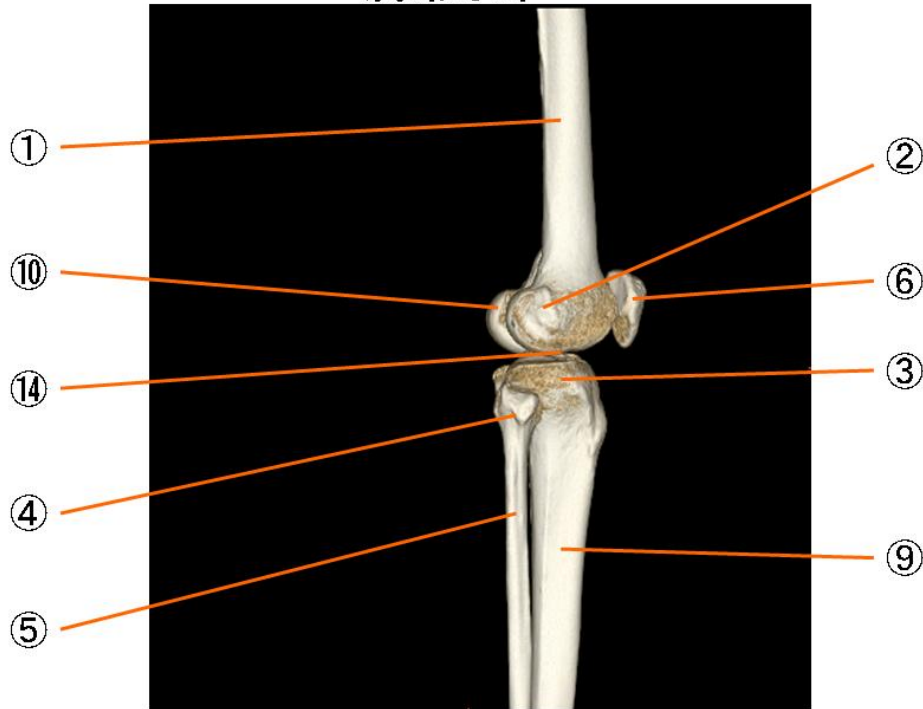
# 膝関節



## 膝関節

① 大腿骨	femur
② 大腿骨の外側上顆	lateral epicondyle of femur
③ 脛骨の外側顆	lateral condyle of tibia
④ 腓骨頭	head of fibula
⑤ 腓骨	fibula
⑥ 膝蓋骨	patella
⑦ 脛骨の内側頭	medial condyle of tibia
⑧ 脛骨粗面	tuberosity of tibia
⑨ 脛骨体	shaft of tibia
⑩ 大腿骨の内側上顆	medial epicondyle of femur
⑪ 大腿骨の外側顆	lateral condyle of femur
⑫ 大腿骨の膝窩面	popliteal surface of femur
⑬ 大腿骨の顆間窩	intercondylar fossa of femur
⑭ 脛骨の顆間隆起	intercondylar eminence of tibia

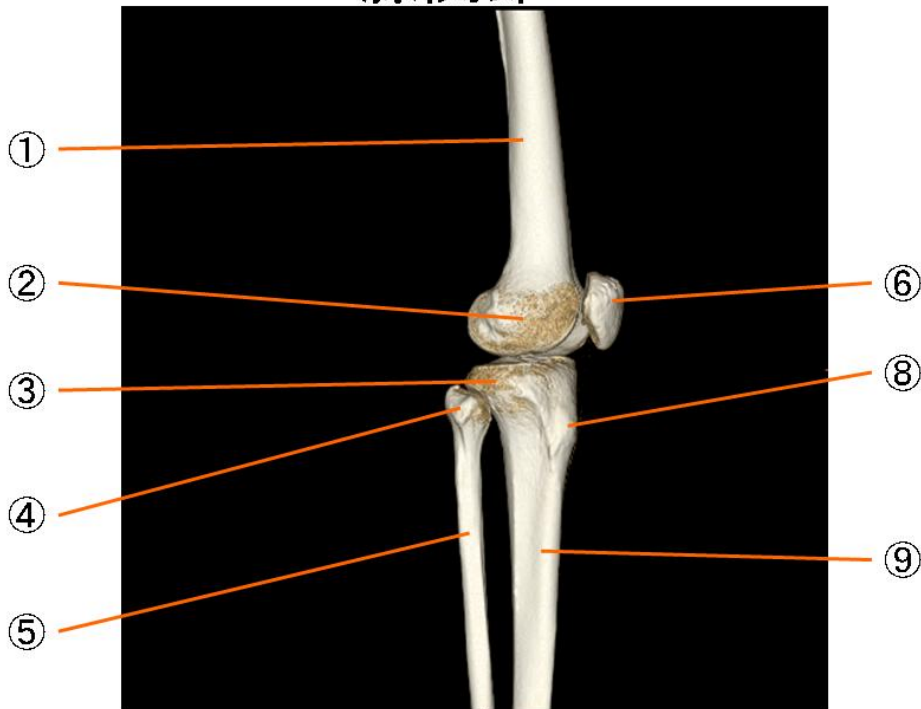
# 膝関節



## 膝関節

- |            |                                 |
|------------|---------------------------------|
| ① 大腿骨      | femur                           |
| ② 大腿骨の外側上顆 | lateral epicondyle of femur     |
| ③ 脛骨の外側顆   | lateral condyle of tibia        |
| ④ 腓骨頭      | head of fibula                  |
| ⑤ 腓骨       | fibula                          |
| ⑥ 膝蓋骨      | patella                         |
| ⑦ 脛骨の内側頭   | medial condyle of tibia         |
| ⑧ 脛骨粗面     | tuberosity of tibia             |
| ⑨ 脛骨体      | shaft of tibia                  |
| ⑩ 大腿骨の内側上顆 | medial epicondyle of femur      |
| ⑪ 大腿骨の外側顆  | lateral condyle of femur        |
| ⑫ 大腿骨の膝窩面  | popliteal surface of femur      |
| ⑬ 大腿骨の顆間窩  | intercondylar fossa of femur    |
| ⑭ 脛骨の顆間隆起  | intercondylar eminence of tibia |

# 膝関節



## 膝関節

- |            |                                 |
|------------|---------------------------------|
| ① 大腿骨      | femur                           |
| ② 大腿骨の外側上顆 | lateral epicondyle of femur     |
| ③ 脛骨の外側顆   | lateral condyle of tibia        |
| ④ 腓骨頭      | head of fibula                  |
| ⑤ 腓骨       | fibula                          |
| ⑥ 膝蓋骨      | patella                         |
| ⑦ 脛骨の内側頭   | medial condyle of tibia         |
| ⑧ 脛骨粗面     | tuberosity of tibia             |
| ⑨ 脛骨体      | shaft of tibia                  |
| ⑩ 大腿骨の内側上顆 | medial epikondyle of femur      |
| ⑪ 大腿骨の外側顆  | lateral condyle of femur        |
| ⑫ 大腿骨の膝窩面  | popliteal surdface of femur     |
| ⑬ 大腿骨の顆間窩  | intercondylar fossa of femur    |
| ⑭ 脛骨の顆間隆起  | intercondylar eminence of tibia |